

## Central Vasomotor Failure in a Patient with Medulla Arteriovenous Fistula

Ching-Hwung Lin<sup>1</sup>, Yuk-Keung Lo<sup>1</sup>, Yuh-Te Lin<sup>1</sup>, Jie-Yuan Li<sup>1</sup>,  
Ping-Hong Lai<sup>2</sup>, and Yung-Yen Gau<sup>1</sup>

**Abstract-** We report on the case of a 60-year-old man who suffered from hiccup, dysphagia and unsteady gait for three months. He was diagnosed with intracranial dural arteriovenous fistula in medulla with retrograde perimedullary vein drainage. He developed quadriplegia, persistent shock status and symptomatic bradycardia immediately after a conventional cerebral angiography study. After excluding cardiogenic, hypovolemic, anaphylactic and septic shock, central vasomotor failure caused by venous thrombosis of the lesion was considered. The patient's central vasomotor failure recovered after continuous dopamine infusion treatment for 42 days. We concluded that venous hypertension with venous thrombosis in rostral ventrolateral medulla (RVLM), a major vasomotor center in the brainstem, was the lesion site. In our case, vasomotor dysfunction caused by an RVLM lesion related to venous thrombosis is considered as causative.

**Key Words:** Vasomotor, AV fistula, Arteriovenous fistula, Medulla

*Acta Neurol Taiwan 2006;15:192-196*

### INTRODUCTION

Intracranial dural arteriovenous fistulas (DAVF) consist of abnormal arteriovenous connections within the dura and they account for 10-15% of all intracranial vascular malformations<sup>(1)</sup>. The etiology of DAVF remains controversial, most authors favor the acquired nature of DAVF. The clinical manifestations of intracranial DAVF are variable, depending on the locations of the fistulas, the types of venous drainage and the flow characteristics of the DAVF. Intracranial DAVF may

present clinical features which can include intracranial hemorrhage, weakness of the upper and/or lower limbs and sphincter disorders, tinnitus and bruit, cranial nerve neuropathy, exophthalmos, headache, hydrocephalus, seizure, focal neurological deficits such as cerebellar or bulbar signs, and global neurological deficits such as dementia<sup>(2)</sup>.

The sympathetic vasomotor nervous system plays a major role in maintaining the level of arterial blood pressure and the distribution of cardiac output<sup>(3)</sup>. Central sympathetic vasomotor neurons in the medulla send pro-

From the <sup>1</sup>Section of Neurology, Department of Medicine;  
<sup>2</sup>Department of Radiology, Kaohsiung Veterans General Hospital, Kaohsiung, Taiwan.

Received June 29, 2005. Revised August 1, 2005.

Accepted January 2, 2006.

Reprint requests and correspondence to: Yuk-Keung Lo, MD, Section of Neurology, Department of Medicine, Kaohsiung Veterans General Hospital, No. 386, Ta-Chung 1St Road, Kaohsiung, Taiwan.

E-mail: yklo@isca.vghks.gov.tw

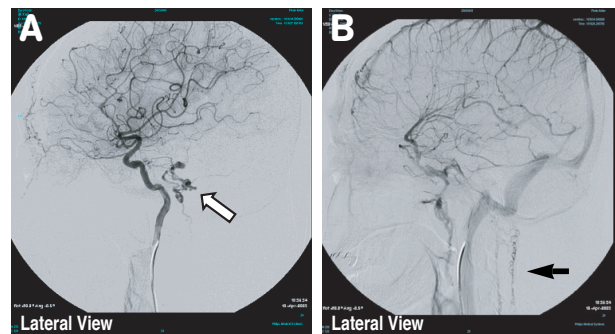
jections to the spinal intermediolateral nucleus, where the preganglionic neurons control heart and blood vessels<sup>(4)</sup>. There is a central vasomotor structure integrating the inputs from peripheral receptors and higher centers in the brain to keep blood pressure and heart rate within normal range.

Here, we report on a case of DAVF in medulla presented with central vasomotor failure. The central vasomotor failure improved after conservative treatment - this is rarely reported.

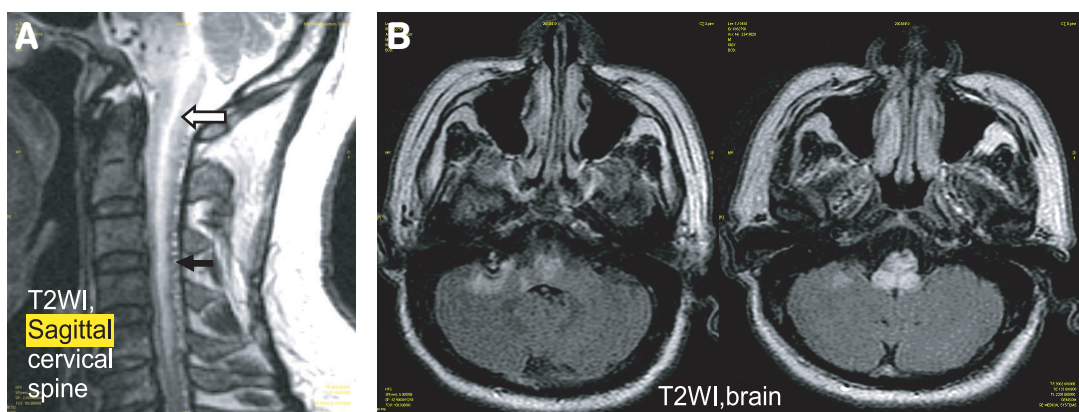
### CASE REPORT

A previously healthy 60-year-old man suffering from hiccup, dysphagia, unsteady gait and four limbs numbness off and on for three months presented for a neurological visit on March 2003. Initial neurological examinations revealed impaired gag reflex, generalized hyperreflexia, bilateral Babinski responses, presence of bilateral Hoffman's signs but absence of jaw jerk. Magnetic resonance imaging (MRI) of the cervical spine and brain (Fig. 1) disclosed an intracranial dural arteriovenous fistula (DAVF) in the medulla region with downward extension to the sixth cervical cord. Conventional angiography (Fig. 2) showed a DAVF with feeding arteries from the right carotid siphon and middle meningeal artery of right external carotid artery. Unfortunately, sig-

nificant weakness in all four limbs occurred immediately after the conventional angiography procedure. Moreover, a state of persistent shock status and symptomatic sinus bradycardia of around 40 beats/minute simultaneously appeared. Repeated MRI studies of the brain and the whole spine showed no newly developed lesions. Venous hypertension with venous thrombosis then became the suspect cause of the acute onset of quadriplegia, persistent shock status and symptomatic sinus bradycardia. We



**Figure 2.** Right carotid angiography shows an intracranial dural AV fistula (white arrow) with the feeding arteries from the right internal carotid siphon and multiple varied directional drainage veins with an engorged and ectatic appearance (A). These veins drain superiorly, posteriorly and medially across the midline. There are prominent retrograde perimedullary veins over the anterior and posterior aspect of the cervical cord region (black arrow) (B).



**Figure 1.** (A) High signal intensity with swelling appearance on T2WI in the medulla region with downward extension to the cervical cord (C-6 level)(white arrow), and combined with multiple signal-void vessels in the spinal canal region of the C spine (black arrow); (B) Post-contrast study showed enhancement of the lesion in the medulla.

prescribed dexamethasone and adequate hydration immediately after the event of quadriplegia. Continuous infusion of atropine/insuprel and dopamine were needed to keep his blood pressure and heart rate stable. A series of dose-response tests were performed during cardiac catheterization and are shown in Table 1 and Table 2. It showed that the stabilization of blood pressure needed dopamine infusion under different pacing rates. Whenever the dosage of dopamine infusion was insufficient, a state of shock re-occurred. Cardiac echography showed normal systolic performance. A permanent pacemaker was implanted for the bradycardia. The dosage of dopamine was tapered progressively and slowly by monitoring his vital signs closely in the Intensive Care Unit. Blood pressure became stable after continuous infusion of dopamine for 42 days. The permanent pacemaker was removed successfully 78 days later.

**Table 1.** Pacing rates and blood pressure levels under the dopamine infusion test (Under dopamine 4.5 ug/Kg/minute)

Pacing rate (per minute)	Blood pressure (mmHg)
60	110/60
70	108/58
80	104/56
90	123/63
100	115/53
110	120/54
120	123/68
130	106/62
140	52/41
150	52/38
160	43/32

**Table 2.** The dosages of dopamine and blood pressure levels under pacing

Dopamine (ug/kg/min)	Blood pressure (mmHg)
Under pacing rate: 80/min	
4.5	141/63
3.8	101/56
3.0	76/46
Under pacing rate: 59/min	
3.2	111/47
1.6	58/32
2.4	94/23

The patient underwent gamma-knife radiosurgery in September 2003 and was cared for in a nursing home able to deal with the chronic nature of this patient's problems. His consciousness was clear and oriented. His muscle power was 3-4/5 over both upper limbs, 1-2/5 over both lower limbs. He had generalized hyperreflexia with clonus, dysarthria, and dysphagia, which required nasogastric tube feeding. He was completely bed ridden. His blood pressure and heart rate were within normal ranges.

## DISCUSSION

It is rare for bulbar signs such as dysphagia and hiccup to be the initial manifestations of intracranial DAVF. Asakawa et al. reported that bulbar symptoms, such as swallowing disturbance, were the last symptom to appear<sup>(5)</sup>. The initial manifestations of DAVF in our patient were bulbar signs such as hiccup and dysphagia for 3 months. Intracranial DAVF in the brainstem region is one of the differential diagnoses of unexplained hiccup and dysphagia.

The five major mechanisms of clinical symptoms of intracranial DAVF are proposed as: 1) Venous hypertension due to impaired venous return; 2) Arterial steal phenomenon; 3) Cerebral compression by dilated venous aneurysm; 4) Intracranial hemorrhage due to venous rupture; and 5) Spontaneous thrombosis. No single mechanism mentioned above could explain all variable features of this case. Most DAVFs are associated with a slow flow with no angiographic evidence of steal<sup>(6)</sup>. So, what is the cause of acute onset of quadriplegia, persistent shock status and symptomatic bradycardia after conventional angiography in our patient? The nature of the event was considered to be vascular origin because the course of the event was acute. The theory of venous hypertension first set forth by Aminoff et al. in 1974, expanded further by Merland et al., and then proved by some pathological studies<sup>(7-9)</sup>. Arteriovenous shunt increased blood volume and led to an increased venous pressure, which reduces the arteriovenous pressure gradient, resulting in decreased perfusion, stagnation of blood flow, edema and hypoxia<sup>(10)</sup>. Oda et al reported a

postmortem case where the spinal cord was edematous with subnecrotic and parenchymal microhemorrhages due to venous congestion. In our patient, the presence of high signal intensity on T2WI over the medulla region with downward extension to the spinal cord at the C6 level shown by MRI image demonstrated an ischemia, and swelling change (edema) of the medulla and upper cervical cord. The strong parenchymal enhancement of the medulla and the cervical spine in our patient constitutes, we concluded, a sign of venous congestion and may represent stagnation of contrast medium within the dilated vessels or the result of a brain-blood barrier disruption due to ischemia. The parenchymal enhancement in the medulla and cervical spinal cord may indicate either reversible pathologic changes, such as edema, or irreversible pathologic changes, such as necrosis from chronic ischemia due to venous hypertension<sup>(5)</sup>. Why is it then that repeated brain MRI's after the conventional angiography showed negative findings despite clinical evidence of quadriplegia and persistent shock status? We concluded that new MRI abnormalities could have been obscured by previous high-intensity lesions in the same region.

Are there any other possible causes which could account for the acute onset of the persistent state of shock and symptomatic sinus bradycardia after conventional angiography? We had excluded the possibilities of septic, hypovolemic and anaphylactic shock by reason of the clinical course of our patient. The drug related bradycardia and shock status were also excluded. Cardiac echography showed normal heart performance. The response of symptomatic bradycardia and shock to atropine/insuprel excludes sinoatrial nodal disease. Moreover, a series of cardiac electrophysiologic tests as recorded in Table 1 and Table 2 showed the blood pressure and heart rate of our patient required clinical management by continuous infusion of inotropic agent and pacemaker support. Both inadequate vasodepression and symptomatic bradycardia contributed to the clinical shock status. There must be the existence of sympathetic and/or vagal neural stimulation. Decreased sympathetic tone only will not induce hypotension. Even after trimethaphan, which completely abrogates all sym-

pathetic tone, systolic blood pressure does not drop down to shock status<sup>(11)</sup>. For hypotension, it may be due to active sympathetic vasodepressor or vagal stimulation. In cases with recurrent neck tumors that activate the carotid sinus nerve, hypotension has been shown to be episodic, not sustained. We had to conclude that the kind of clinical picture we were seeing could only be seen in cases of brainstem lesion related central vasomotor failure. Manelfe et al. reported severe dysautonomic disorders (postural hypotension, hypertension, episodes of bradycardia, alternating with tachycardias) in a DAVF patient<sup>(12)</sup>. Unlike our patient, their patient presented with transient or episodic dysautonomic disorder, but not sustained. Niki et al reported a patient with posterior fossa DAVF with progressive dysfunction of cerebellar circulation<sup>(13)</sup>. To the best of our knowledge, our patient may be the first reported case of intracranial DAVF related brainstem infarction. The cause of brainstem infarction was considered due to venous hypertension with venous thrombosis.

Where is the anatomical and functional location of the brainstem infarction in our patient? The basal sympathetic vasomotor tone/activity allows central neural mechanism to increase or decrease regional vascular resistance and heart rate in response to various environments. Regions of central nervous system involved in cardiovascular control have been recognized and include the medial prefrontal cortex, insular cortex, hypothalamus, the main bulbar nuclei such as the rostral ventral lateral medulla (RVLM), the dorsal nucleus of the vagus and the nucleus tractus solitarius<sup>(14)</sup>. Electrophysiological studies have proven that cortical regions can influence premotor sympathoexcitatory vasomotor neurons within the RVLM and subsequently change sympathetic vasomotor tone. RVLM, a major vasomotor center in the brainstem, consists of sympathetic premotor neurons responsible for generating and maintaining basal vasomotor tone and resting arterial blood pressure. The inhibition of RVLM neurons either due to drug injection or pathologic damage may reduce arterial pressure and bring about bradycardia<sup>(15)</sup>. In contrast, stimulation of neurons in the RVLM may elevate arterial pressure<sup>(16)</sup>. RVLM play a critical role in central sympathetic vaso-

motor tone. But the above mentioned clinical result is only proved in animal studies. Our patient presented with sustained hypotension and bradycardia. His vital signs required management by permanent pacemaker and continuous infusion of inotropic agents. We concluded that the functional and anatomical location of the venous hypertension with venous thrombosis might be localized in the medullar region involving the RVLM.

In conclusion, intracranial DAVF should be considered to be one of the differential diagnosis of bulbar symptoms or myelopathy. A central vasomotor dysfunction should be considered in the event of acute onset of persistent shock status and symptomatic bradycardia after excluding other possibilities. After conservative treatment to stabilize hemodynamics, central vasomotor failure may improve gradually.

## REFERENCES

- Cognard C, Gobin YP, Pierot L, et al. Cerebral dural arteriovenous fistulas: clinical and angiographic correlation with a revised classification of venous drainage. *Radiology* 1995;194:671-80.
- Matsuda S, Waragai M, Shinotoh H, et al. Intracranial dural arteriovenous fistula (DAVF) presenting progressive dementia and parkinsonism. *J Neurol Sci* 1999;165:43-7.
- Dampney RA, Coleman MJ, Fontes MA, et al. Central mechanisms underlying short- and long-term regulation of the cardiovascular system. *Clin Exp Pharmacol Physiol* 2002;29:261-8.
- Viltart O, Mullier O, Bernet F, et al. Motor cortical control of cardiovascular bulbar neurones projecting to spinal autonomic areas. *J Neurosci Res* 2003;73:122-35.
- Asakawa H, Yanaka K, Fujita K, et al. Intracranial dural arteriovenous fistula showing diffuse MR enhancement of the spinal cord: case report and review of the literature. *Surg Neurol* 2002;58:251-7.
- Kim MS, Han DH, Kwon OK, et al. Clinical characteristics of dural arteriovenous fistula. *J Clin Neurosci* 2002;9:147-55.
- Aminoff MJ, Barnard RO, Logue V. The pathophysiology of spinal vascular malformations. *J Neuro Sci* 1974;23:255-63.
- Merland JJ, Riche MC, Chiras J. Intraspinous extramedullary arteriovenous fistulae draining into the medullary veins. *J Neuroradiol* 1980;7:271-320.
- Hurst RW, Kenyon LC, Lavi E, et al. Spinal dural arteriovenous fistula: the pathology of venous hypertensive myelopathy. *Neurology* 1995;45:1309-13.
- Wiesmann M, Padovan CS, Pfister HW, et al. Intracranial dural arteriovenous fistula with spinal medullary venous drainage. *Eur Radiol* 2000;10:1606-9.
- Vasquez EC, Lewis SJ, Varner KJ, et al. Chronic lesion of rostral ventrolateral medulla in spontaneously hypertensive rats. *Hypertension* 1992;19(2 Suppl):II154-8.
- Ricolfi F, Manelfe C, Meder JF, et al. Intracranial dural arteriovenous fistulae with perimedullary venous drainage. Anatomical, clinical and therapeutic considerations. *Neuroradiology* 1999;41:803-12.
- Niki Y, Tanaka Y, Hashimoto H, et al. Posterior fossa dural arteriovenous fistula with progressive disorder of cerebellar circulation; case report. *No Shinkei Geka* 1996;24:455-8.
- Sequeira H, Viltart O, Ba-M'Hamed S, et al. Cortical control of somato-cardiovascular integration: neuroanatomical studies. *Brain Res Bull* 2000;53:87-93.
- Chan JY, Wang LL, Ou CC, et al. Downregulation of angiotensin subtype 1 receptor in rostral ventrolateral medulla during endotoxemia. *Hypertension* 2003;42:103-9.
- Ito S, Komatsu K, Tsukamoto K, et al. Ventrolateral medulla AT1 receptors support blood pressure in hypertensive rats. *Hypertension* 2002;40:552-9.